

## Endosonographic Findings in Colitis Cystica Profunda

Mohamed Sultan, MD<sup>1</sup>, Walid Chalhoub, MD<sup>1</sup>, Klaus Gottlieb, MD<sup>2</sup>, and Gustavo Marino, MD<sup>2</sup>

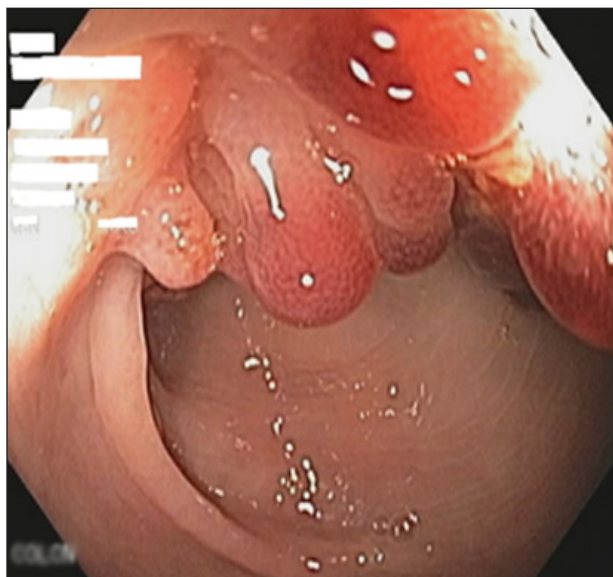
<sup>1</sup>Division of Gastroenterology, MedStar Georgetown University Hospital, Washington, DC

<sup>2</sup>Division of Gastroenterology, Veteran Affairs Medical Center, Washington, DC

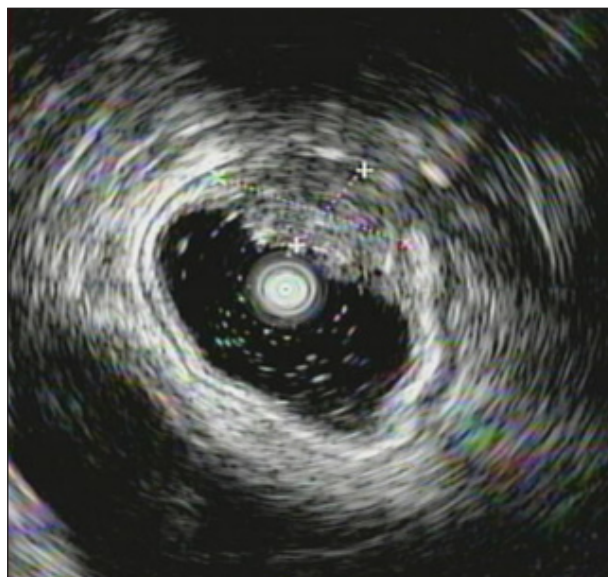
### Case Report

A 27-year-old male was referred to our institution for further evaluation of persistent rectal bleeding. A prior colonoscopy showed a sigmoid soft tissue lesion, and pathology revealed chronic active colitis and granulation tissue with ulcers and focal adenomatous changes. We performed a flexible sigmoidoscopy that showed a 4.5-cm multilobulated polypoid lesion approximately 45 cm from the anal verge (Figure 1). A 20 MHz Olympus endoscopic ultrasound (EUS) miniprobe showed hypoechoic lesion with cystic/spongy features involving the mucosa and submucosa (Figure 2). These features were thought to suggest colitis cystica profunda (CCP). Histologic examination of snare biopsies identified dilated glands with mucinous content, surrounded by variable degrees of fibrosis on a background of interspersed chronic inflammatory cells, with few colonic mucosal crypts and mild inflammatory cell infiltrate (Figure 3). The patient was instructed to follow up with gastroenterology if bleeding recurred.

CCP is a rare, benign disease of the colon and rectum often mimicking malignancy. It was first described in 1766 by Stark, who reported 2 cases associated with dysentery.<sup>1</sup> Histologically, it is characterized by dilated mucous glands mostly limited to the submucosa, but there are reported cases of penetration to the muscularis mucosa.<sup>1</sup> The etiology of CCP remains controversial; however, many consider solitary rectal ulcer syndrome (SRUS) and



**Figure 1.** Endoscopic image of CCP showing polypoid lesion with lobulated appearance and some hemorrhagic areas with normal surrounding mucosa.

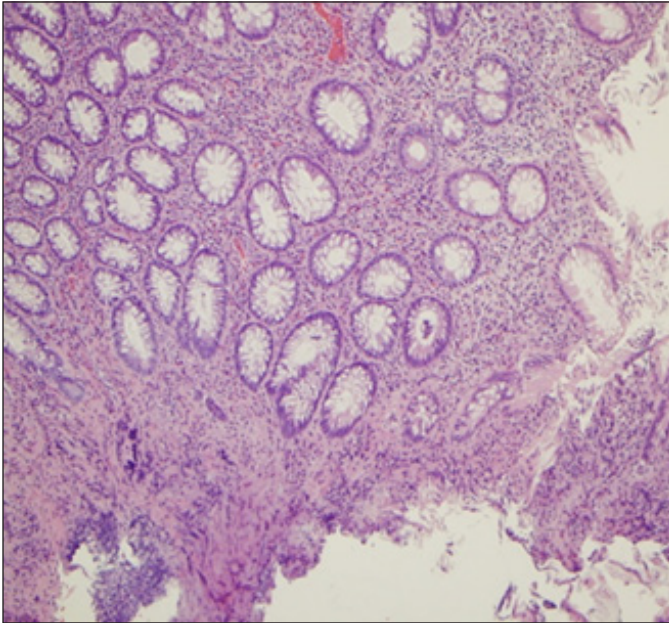


**Figure 2.** EUS showing hypoechoic lesion with cystic/spongy features, with involvement of the mucosa and submucosal. The muscularis propria appears intact.

*ACG Case Rep J* 2014;1(3):122–123. doi:10.14309/crj.2014.23. Published online: April 4, 2014.

**Correspondence:** Mohamed Sultan, Georgetown University Hospital, Gastroenterology, 3800 Reservoir Rd. NW, 5th Floor PHC Building, Department of Medicine, Washington, DC, 20007 (mhod772000@yahoo.ca).

**Copyright:** © 2014 Sultan et al. This is an open-access article distributed under the terms of the Creative Commons Attribution License, which permits unrestricted use, distribution, and reproduction in any medium, provided the original author and source are credited.



**Figure 3.** Hematoxylin and eosin stain section showing transmural dilated glands with mucinous content, surrounded by variable degrees of fibrosis on a background of interspersed chronic inflammatory cells and few colonic mucosal crypts, with mild inflammatory cells infiltrate.

CCP to be different manifestations of the same pathology due to overlapping features.<sup>2</sup> Surface mucosal biopsies may rule out neoplasia, but only deep biopsies show characteristic histological features.<sup>1</sup> There are few case reports of the endosonographic features of CCP,<sup>3</sup> which include multiple hypoechoic or anechoic lesions affecting mucosa or submucosa, with areas of echorefringent fibrosis between lesions in the absence of lymph node enlargement. EUS was instrumental in making our diagnosis and providing proper counseling to the patient.

## Disclosures

Author contributions: All authors contributed equally to this article. M. Sultan is the article guarantor.

Financial disclosure: The authors have no financial disclosure.

Informed consent was obtained for this case report.

Received: December 9, 2013; Accepted: March 4, 2014

## References

1. Guest CB, Reznick RK. Colitis cystica profunda: Review of the literature. *Dis Colon Rectum*. 1989;32(11):983–8.
2. Vora IM, Sharma J, Joshi AS. Solitary rectal ulcer syndrome and colitis cystica profunda. A clinico-pathological review. *Indian J Pathol Microbiol*. 1992;35(2):94–102.
3. Hulsmans FJ, Tio TL, Reeders JW, Tytgat GN. Transrectal US in the diagnosis of localized colitis cystica profunda. *Radiology*. 1991;181(1):201–3.

## Publish your work in ACG Case Reports Journal

ACG Case Reports Journal is a peer-reviewed, open-access publication that provides GI fellows, private practice clinicians, and other members of the health care team an opportunity to share interesting case reports with their peers and with leaders in the field. Visit <http://acgcasereports.gi.org> for submission guidelines. Submit your manuscript online at <http://mc.manuscriptcentral.com/acgcr>.