

Parastomal Variceal Bleeding Attributed to Obstructive Pathology Successfully Treated by Percutaneous Variceal Embolization

Yutaka Tomizawa, MD, Atsushi Sakuraba, MD, PhD, and Joel Pekow, MD

Department of Medicine, Section of Gastroenterology, Hepatology, and Nutrition, The University of Chicago, Chicago, IL

Abstract

Parastomal variceal bleeding is a rare cause of gastrointestinal bleeding, but it should be considered as a potential etiology in patients with portal hypertension and surgical stomas. Though standard endovascular management has not yet been established, transjugular intrahepatic portosystemic shunt (TIPS) is a recommended treatment option leading to decompression of underlying portal hypertension. We present a case of parastomal bleeding treated with percutaneous parastomal variceal embolization, which is an emerging alternative therapy when TIPS cannot be performed.

Introduction

Variceal bleeding is a gastrointestinal emergency where prompt and accurate assessment of the cause, location, and severity is warranted. Parastomal variceal bleeding typically occurs in patients with portal hypertension and surgical stomas. Surgical revision is not recommended in many cases given cirrhosis and portal hypertension. Transjugular intrahepatic portosystemic shunt (TIPS) is often the preferred treatment option because of the high prevalence of underlying portal hypertension, but percutaneous parastomal variceal embolization is an emerging alternative therapy when TIPS cannot be performed.

Case Report

A 58-year-old woman with ileocolonic Crohn's disease status post total proctocolectomy with end ileostomy and chronic liver disease presented with recurrent gross bleeding into an ostomy bag. She previously underwent multiple small bowel resections with stoma revision complicated by short bowel syndrome and parenteral nutrition (PN) dependency. She was diagnosed with PN-associated liver fibrosis confirmed by liver biopsy and portal hypertension with portal venous pressure of 21 mm Hg. She developed recurrent severe hepatic encephalopathy requiring multiple hospitalizations despite optimal medical prophylactic therapy. Crohn's disease had been in clinical remission on low-dose budesonide.

The patient presented with multiple episodes of blood in her ostomy bag and a drop in hemoglobin to 7.7 g/dL. Esophagogastroduodenoscopy showed non-bleeding portal hypertensive gastropathy with no varices, and ileoscopy showed no active bleeding. Her liver function was still compensated based on synthetic function (INR 1.3; albumin 3.3 g/dL) and normal hepatopetal flow seen on Doppler abdominal ultrasound. Tagged red blood cell scan did not reveal active bleeding. Computed tomography enterography demonstrated the presence of parastomal varices within a large parastomal hernia fed by an afferent vein originating from the superior mesenteric

ACG Case Rep J 2014;1(4):217–219. doi:10.14309/crj.2014.58. Published online: July 8, 2014.

Correspondence: Yutaka Tomizawa, MC 4076, Room M421, 5841 S. Maryland Ave, Chicago, IL 60637 (yutaka.tomizawa@uchospitals.edu).

Copyright: © 2014 Tomizawa et al. This is an open-access article distributed under the terms of the Creative Commons Attribution License, which permits unrestricted use, distribution, and reproduction in any medium, provided the original author and source are credited.

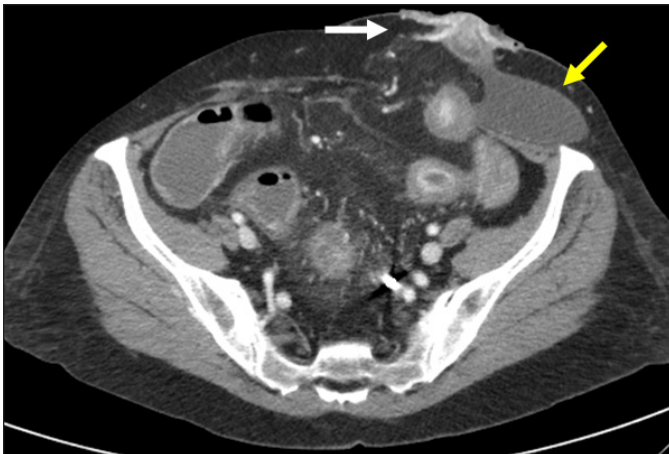


Figure 1. Afferent feeding vein originating from the superior mesenteric vein (white arrow) draining to parastomal varices and parastomal hernia (yellow arrow).

vein (Figure 1). It was thought the bleeding was related to parastomal varices, which were predisposed by portal hypertension and increased intravascular pressure from the short segment stricture at the abdominal wall related to the parastomal hernia sac. The bleeding stopped spontaneously and she remained hemodynamically stable for the rest of hospital stay with adequate response to blood transfusion. She was started on nadolol and discharged home.

Six months later, she presented with a recurrent episode of gross blood in her ostomy bag with drop in hemoglobin, but bloody stoma output stopped spontaneously after admission. Surgeons evaluated the patient, but stoma revision was not recommended due to the risk of short bowel and possible recurrence of the parastomal hernia. She was discharged home with conservative management. Three months later, she presented again with gross blood in her ostomy bag with drop in

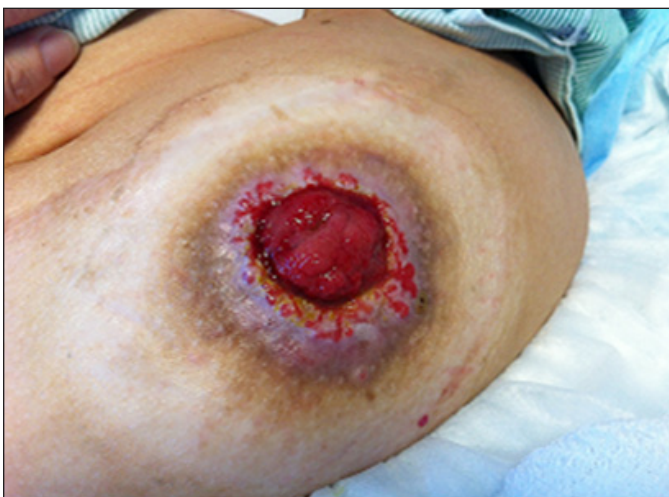

Figure 2. No visible bleeding sites in the protruded stoma or adjacent skin at bedside inspection.

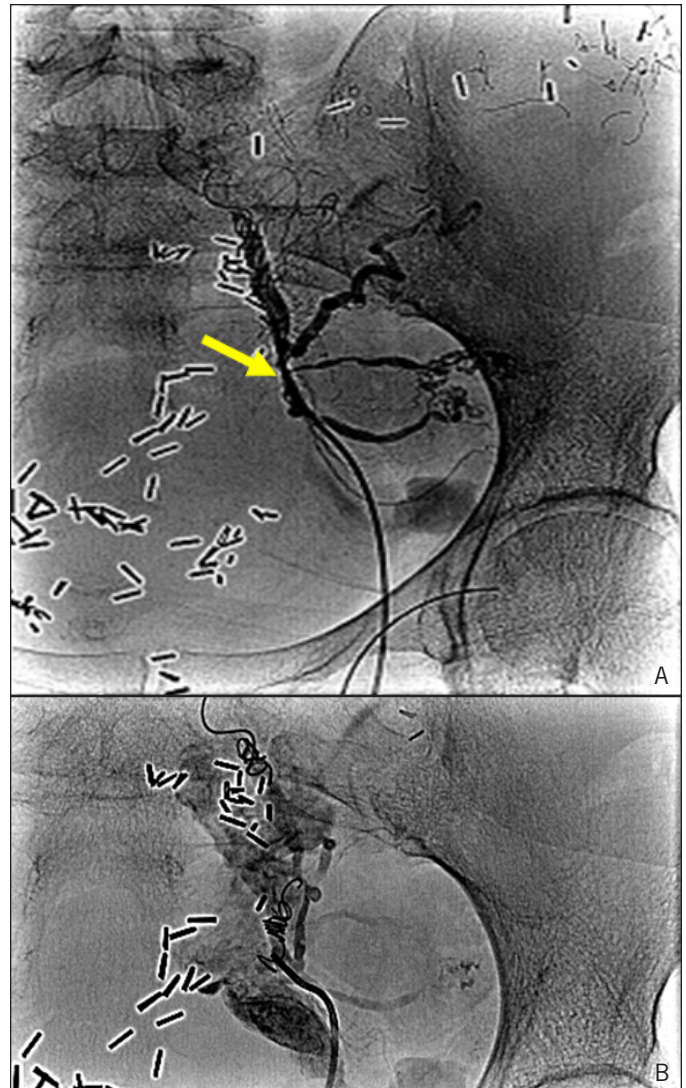


Figure 3. (A) Pre-embolization venogram showed afferent vein (arrow) draining to peristomal varices. (B) Post-embolization after coil deployment at the point of flow reversal demonstrated cessation of flow in the peristomal varices.

hemoglobin. At bedside evaluation, there were no apparent bleeding sites in the protruded stoma or adjacent skin (Figure 2). Repeat ileoscopy showed normal neo-terminal ileal mucosa without evidence of active inflammation or bleeding. Percutaneous parastomal variceal embolization was performed; under direct Doppler ultrasonographic guidance, a portal venous branch was accessed with a micropuncture needle and a guidewire was advanced. Over a guidewire, an angiographic catheter was placed and venogram was performed, which confirmed the afferent vein draining into the parastomal varices with hepatofugal flow (Figure 3). Coils were deployed for embolization at the point of flow reversal. Follow-up venogram demonstrated cessation of flow into the parastomal varices (Figure 3). She has had no bleeding events in the 5 months following this procedure.

Discussion

Parastomal variceal bleeding accounts for less than 5% of all variceal bleeding.¹ Although parastomal varices usually occur in the setting of portal hypertension, they sometimes occur under local or segmental obstructive pathology due to postsurgical changes. These varices develop at the mucocutaneous junction from spontaneous anastomoses between portal venous branches in the stoma and systemic venous branches in the abdominal wall.² Parastomal variceal bleeding can be severe enough to cause symptomatic anemia or hemodynamic instability, warranting urgent or emergent treatment.³ Surgical revision of the ostomy is one of the treatment options, though it is not recommended in many cases due to cirrhosis and portal hypertension. Endovascular therapy has been advocated as an alternative therapeutic option, and TIPS is the most preferred modality as it leads to decompression of underlying portal hypertension.⁴

Bleeding has been reported after successful reduction of portal pressure to less than 12 mm Hg, which suggests that the threshold of portal pressure leading to parastomal variceal bleeding may be lower than for esophageal or gastric varices. The use of subcutaneous octreotide may reduce acute hemorrhage and should be considered only for intermittent use, as pharmacotherapy is ineffective as monotherapy.¹ Percutaneous parastomal varices embolization is an emerging interventional radiologic technique. Since the patient had a history of recurrent hepatic encephalopathy, we elected for this procedure.

Contrast-enhanced cross-sectional imaging is useful to rule out portal venous thrombosis and to evaluate anatomy of afferent and efferent venous circulation. The mesenteric venous feeder is identified carefully by Doppler ultrasound to make sure its flow is toward the stoma. The portal venous feeder is accessed under real-time ultrasound using a micropuncture for venography. Embolization is performed by administration of a sclerosant and/or coil deployment.⁵ The benefits of percutaneous embolization over TIPS are lack of general anesthesia, shorter procedure time, and availability in cases where TIPS cannot be performed due to hepatic encephalopathy or portal vein thrombosis. The drawbacks are the risk of bleeding and that it does not treat the underlying portal hypertension. This modality, however, can be reattempted in cases of recurrent bleed after treatment. The largest retrospective case series (n=8) to date, in which all embolizations were performed with coils combined with a

sclerosant, reported 88% success rate. With median follow-up of 255 days, recurrent bleeding occurred in 3 cases with median time to re-bleeding of 45 days. No bleeding-related mortality was found.⁶

We present a unique case of parastomal variceal bleeding attributed not only to portal hypertension but also to obstructive pathology. It highlights that parastomal varices are a potential cause of gastrointestinal bleeding in patients with stoma, particularly in the setting of portal hypertension and vascular compression. Though TIPS is the recommended treatment option, percutaneous embolization is an alternative therapy when TIPS cannot be performed.

Disclosures

Author contributions: Y. Tomizawa acquired, analyzed, and interpreted the data, and drafted the manuscript. A. Sakuraba supervised the manuscript writing and is the article guarantor. J. Pekow critically reviewed the manuscript.

Financial disclosure: None to report.

Informed consent was obtained for this case report.

Received: December 12, 2013; Accepted: May 8, 2014

References

1. Spier BJ, Fayyad AA, Lucey MR, et al. Bleeding stomal varices: Case series and systematic review of the literature. *Clin Gastroenterol Hepatol*. 2008;6(3):346–52.
2. Ryu RK, Nemcek AA Jr, Chrisman HB, et al. Treatment of stomal variceal hemorrhage with TIPS: Case report and review of the literature. *Cardiovasc Intervent Radiol*. 2000;23(4):301–3.
3. Norton ID, Andrews JC, Kamath PS. Management of ectopic varices. *Hepatology*. 1998;28(4):1154–8.
4. Vangeli M, Patch D, Terreni N, et al. Bleeding ectopic varices: Treatment with transjugular intrahepatic porto-systemic shunt (TIPS) and embolization. *J Hepatol*. 2004;41(4):560–6.
5. Saad WE, Saad NE, Koizumi J. Stomal varices: Management with decompression tips and transvenous obliteration or sclerosis. *Tech Vasc Interv Radiol*. 2013;16(2):176–84.
6. Pabon-Ramos WM, Niemeyer MM, Dasika NL. Alternative treatment for bleeding peristomal varices: Percutaneous parastomal embolization. *Cardiovasc Intervent Radiol*. 2013;36(5):1399–1404.

Publish your work in ACG Case Reports Journal

ACG Case Reports Journal is a peer-reviewed, open-access publication that provides GI fellows, private practice clinicians, and other members of the health care team an opportunity to share interesting case reports with their peers and with leaders in the field. Visit <http://acgcasereports.gi.org> for submission guidelines. Submit your manuscript online at <http://mc.manuscriptcentral.com/acgcr>.