

A Rare Case of Dual Cecae

Santosh K. Mupparapu, MD, MPH,¹ and Michael A. Pezzone, MD, PhD, AGAF^{2,3,4}

¹Department of Critical Care Medicine, University of Pittsburgh Medical Center, Pittsburgh, PA

²Department of Pharmacology and Chemical Biology, University of Pittsburgh, Pittsburgh, PA

³The McGowan Institute for Regenerative Medicine, University of Pittsburgh, Pittsburgh, PA

⁴Washington Health System, Washington, PA

Case Report

An 18-year-old woman presented with crampy upper abdominal pain for 16 months. An esophagogastroduodenoscopy 1 year prior was notable only for heterotopic pancreatic tissue in the gastric antrum. Past history included asthma and congenital genitourinary and pelvic malformations with multiple urological surgeries and genitoplasty. Abdominal examination showed scars from previous surgeries but was otherwise normal. An abdominal and pelvic computed tomography showed left-sided hydronephrosis, partial duplication of the urinary bladder, and duplication of uterus and cervix. A colonoscopy showed no evidence of macroscopic colitis. Surprisingly, 2 cecae were noted, each with its own appendiceal orifice. The terminal ileum had a normal appearance and was intubated via a triangular valve between the 2 cecae (Figure 1). Biopsies from colon and terminal ileum were normal.

Duplications of the gastrointestinal tract are rare and have a reported incidence of 1 in 5,000 live births.¹ Only about 17% of these are located in the colon and rectum, with an incidence of 0.004%.² Duplications of the appendix can be classified by the Cave-Wallbridge classification. In type A, there is partial duplication, and both the appendices have a common base. In type B, a single cecum has 2 completely separate appendices. Type C is a double cecum, each with its own appendix, as in this case. Most of these are also associated with other hindgut duplications.^{3,4} This case had no other associated gastrointestinal duplications, and both cecae communicated with the terminal ileum and ascending colon, increasing the rarity of the report.

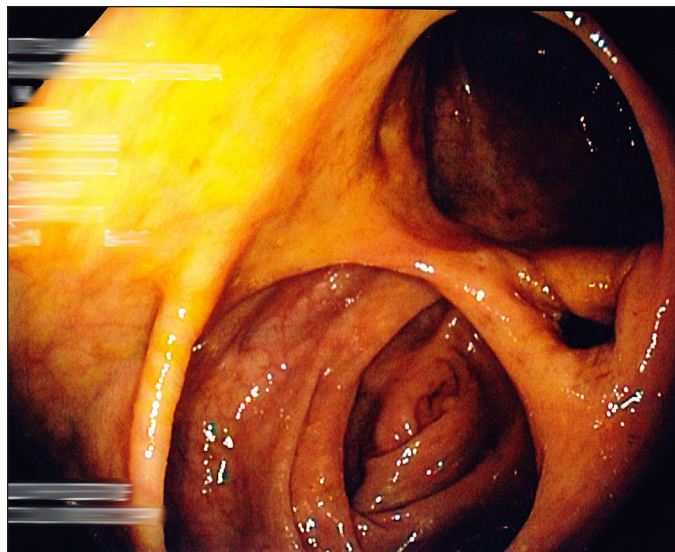


Figure 1. Colonoscopy showing double cecae and the ileocecal valve.

Disclosures

Author contributions: SK Mupparapu wrote the manuscript and performed the literature review. MA Pezzone edited and reviewed the manuscript, and is the article guarantor.

Financial disclosure: None to report.

Informed consent was obtained for this case report.

Received: October 13, 2014; Accepted: December 16, 2014

References

1. Currie AB, Hemalatha VH, Doraiswamy NV. Duplications of the alimentary tract. *J R Coll Surg Edinb.* 1978;23(6):347–354.
2. Heiss K. Intestinal duplications. In: Oldham KT, Colombani PM, Foglia RP, eds. *Surgery of Infants and Children: Scientific Principles and Practice.* Philadelphia, PA: Lippincott-Raven; 1997.
3. Wallbridge PH. Double appendix. *Br J Surg.* 1962;50:346–7.
4. Coker DD, Hartong JM, Conklin HB. Duplication of the vermiform appendix: Case report. *Mil Med.* 1975;140(5):331–2.

ACG Case Rep J 2015;2(2):76. doi:10.14309/crj.2015.8. Published online: January 16, 2015.

Correspondence: Michael A. Pezzone, Department of Pharmacology and Chemical Biology, The McGowan Institute for Regenerative Medicine, University of Pittsburgh School of Medicine, The University of Pittsburgh Medical Center, 3550 Terrace St, Pittsburgh, PA 15261 (pezzone@pitt.edu).



Copyright: © 2015 Mupparapu et al. This work is licensed under a Creative Commons Attribution-NonCommercial-NoDerivatives 4.0 International License. To view a copy of this license, visit <http://creativecommons.org/licenses/by-nc-nd/4.0>.