

Idiopathic Esophageal Ulcers in AIDS Completely Healed With Highly Active Anti-Retroviral Therapy

David J. Bromberg, MD¹ and Jeffrey A. Gill, MD²

¹Department of Internal Medicine, University of South Florida Morsani College of Medicine, Tampa, FL

²Department of Gastroenterology, Division of Digestive Diseases and Nutrition, James A. Haley Veterans Affairs Hospital, University of South Florida, Tampa, FL

Case Report

A 51-year-old white man presented to the emergency department with a 3-month history of atypical chest pain, odynophagia to solids and liquids, and a 18-kg weight loss. He was febrile to 39°C and tachycardic. Physical exam was remarkable for bilateral submandibular lymphadenopathy and thrush in the posterior oropharynx. He was diagnosed with AIDS with CD4 count 146 cells/mm³ and viral load 423,000 copies/mL. Esophagogastroduodenoscopy (EGD) showed a large, deep, irregular esophageal ulcer (Figure 1). Biopsies of the ulcer margins and bases were negative for malignancy or infection. He was diagnosed with an idiopathic esophageal ulcer (IEU) secondary to AIDS. He was started on a proton pump inhibitor and highly active anti-retroviral therapy (HAART). Three weeks later, repeat EGD revealed complete resolution of the esophageal ulcer (Figure 2). More than 1 year after diagnosis, he continued to do well with a viral load of 53, CD4 count of 708, and without any recurrence of odynophagia.

The gastrointestinal tract—particularly the esophagus—can have disease involvement in up to 40% of AIDS patients not on HAART.¹ Herpes simplex virus typically causes shallow ulcers, whereas cytomegalovirus (CMV) often affects the distal esophagus with very large and deep ulcers. CMV ulcers and IEUs often have a similar appearance endoscopically, and require multiple biopsies to differentiate. Kaposi sarcoma is the most common esophageal neoplasm with typical-appearing bulky purple-tinged mucosa with submucosal nodular lesions.¹ The diagnosis of IEU is one of exclusion after endoscopy with multiple biopsies. The pathogenesis of IEU formation is hypothesized to be from T-cell activation and subsequent apoptosis of the esophageal mucosa.²

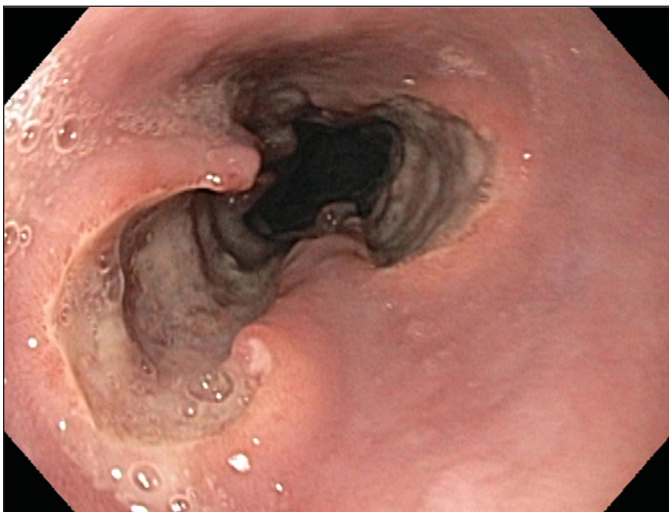

Figure 1. An idiopathic esophageal ulcer of the distal esophagus prior to initiation of HAART.

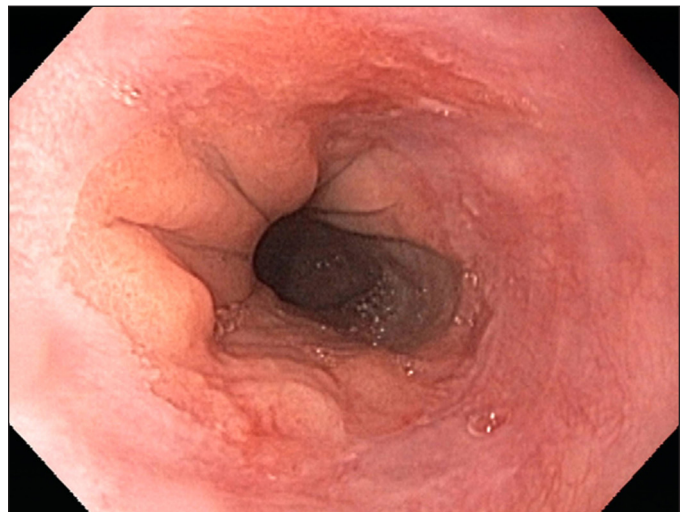


Figure 2. The resolved esophageal ulcer after less than 3 weeks of HAART.

ACG Case Rep J 2015;2(3):127-128. doi:10.14309/crj.2015.28. Published online: April 10, 2015.

Correspondence: Jeffrey A. Gill, Department of Gastroenterology, Division of Digestive Diseases and Nutrition, James A. Haley Veterans Affairs Hospital, University of South Florida, 13000 Bruce B. Downs Blvd. Tampa, FL, 33612 (Jeffrey.Gill@va.gov).



Copyright: © 2015 Bromberg et al. This work is licensed under a Creative Commons Attribution-NonCommercial-NoDerivatives 4.0 International License. To view a copy of this license, visit <http://creativecommons.org/licenses/by-nc-nd/4.0>.

Numerous possible inducers of apoptosis have been identified, including cytokines from HIV, tumor necrosis factor- α , and bacterial toxins.³ Treatment of IEUs should target the underlying AIDS virus with HAART. This case demonstrates that even the largest IEUs can be healed by immune reconstitution with HAART and acid suppression.

Disclosures

Author contributions: DJ Bromberg wrote the manuscript and is the article guarantor. JA Gill conceptualized, edited, and approved the manuscript.

Financial disclosure: None to report.

Informed consent was obtained for this case report.

Received: January 28, 2015; Accepted: March 18, 2015

References

1. Wilcox CM. Endoscopy in AIDS: A pattern approach to diagnosis. *Vis Hum J Endosc.* 2005;4:7–10.
2. Hamada Y, Nagata N, Honda H, et al. Idiopathic oropharyngeal and esophageal ulcers related to HIV infection successfully treated with antiretroviral therapy alone. *Intern Med.* 2013;52:393(3)–395.
3. Houghton J, Korah JM, Kyung HK, et al. A role for apoptosis in the pathogenesis of AIDS-related idiopathic esophageal ulcers. *J Infect Dis.* 1997;175(5):1216–1219.

Publish your work in ACG Case Reports Journal

ACG Case Reports Journal is a peer-reviewed, open-access publication that provides GI fellows, private practice clinicians, and other members of the health care team an opportunity to share interesting case reports with their peers and with leaders in the field. Visit <http://acgcasereports.gi.org> for submission guidelines. Submit your manuscript online at <http://mc.manuscriptcentral.com/acgcr>.