

Polyethylene Glycol (PEG)-Induced Anaphylactic Reaction During Bowel Preparation

David Gachoka, MD

Department of Internal Medicine, University of Toledo, Toledo, OH

Abstract

Barium enema is used to screen patients with gastrointestinal bleeding who do not want to undergo colonoscopy. Polyethylene glycol (PEG) is usually the bowel preparation of choice. Few allergic reactions from this product have been reported; these include urticaria, angioedema, and anaphylaxis. Reactions are thought to result from a small amount of PEG crossing the intestinal mucosa, which, in some patients, is sufficient to provoke an anaphylactic reaction.

Introduction

Complications from polyethylene glycol (PEG) solutions are rare, with abdominal discomfort, cramping, and nausea cited most frequently in the literature.¹ Generally, PEG products are considered as safe as other bowel preparation agents due to their large molecular size, which reduces their absorption across the intestinal mucosa. Even then, about 0.2% can still be absorbed, of which about 0.06% is recovered in the urine.^{2,3} Few cases of severe allergic reaction such as anaphylaxis and anaphylactic shock have been reported.^{4,5,1,6} Three other cases of non-severe allergic reactions such as urticaria and angioedema have also been reported.^{2,7,3} This amount of allergen, though small, can provoke systemic anaphylactic reaction in susceptible individuals.

Case Report

A 74-year-old man with past medical history of hypertension, atrial fibrillation, diastolic congestive heart failure, and no known allergies prepared for outpatient barium enema to evaluate progressive anemia without overt bleeding. A day before the procedure, he started preparation with clear liquids, then progressed to HalfLytely® (Braintree Laboratories, Braintree, MA), a PEG product composed of PEG-3350, sodium chloride, sodium bicarbonate, potassium chloride, flavoring, and bisacodyl tablets. Two hours later, he experienced a diffuse tingling sensation in his throat, and as he finished the preparation, his throat started to tighten and his voice became hoarse. He went to sleep, only to wake up 30 minutes later with a “lump-like” choking sensation, hoarse voice, and swollen tongue, with noticeable erythema of his anterior neck.

On presentation, his temperature was 36.4° C, pulse 102 bpm, blood pressure 102/65 mm Hg, and oxygen saturation 93% on room air. Physical exam revealed anicteric eyes, clear chest bilaterally, mild regular tachycardia, normal abdomen, and normal integument. X-ray showed a prominent epiglottis suggesting edema; follow-up contrast CT of the neck showed laryngeal edema with airway narrowing (Figure 1). He was given empiric treatment with albuterol and decadron, followed by methylprednisolone and cetirizine, with intravenous saline resuscitation; however, his blood pressure continued to drop, with persistent upper airway symptoms. An arterial blood gas on 2 L of oxygen via nasal cannula revealed pH 7.39, partial pressure of carbon dioxide 38 mm, and partial pressure of oxygen 89 mm Hg. He was given an epinephrine injection and inhaled racemic epinephrine,

ACG Case Rep J 2015;2(4):216-217. doi:10.14309/crj.2015.63. Published online: July 9, 2015.

Correspondence: David Gachoka, The University of Toledo Medical Center, 3000 Arlington Avenue, Toledo, OH, 43614 (david.gachoka@utoledo.edu; gachokad@outlook.com).



Copyright: © 2015 Gachoka. This work is licensed under a Creative Commons Attribution-NonCommercial-NoDerivatives 4.0 International License. To view a copy of this license, visit <http://creativecommons.org/licenses/by-nc-nd/4.0>.

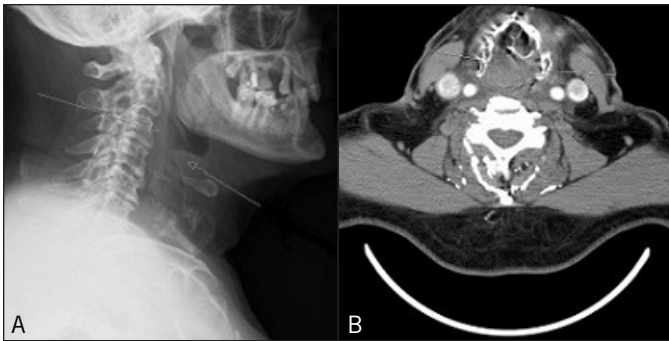


Figure 1. (A) Prominent epiglottis suggesting edema. (B) Laryngeal edema with airway narrowing.

which improved his symptoms and normalized his vital signs within 7 minutes. He was admitted for observation with standby repeat epinephrine injection if his symptoms rebounded. His symptoms completely resolved overnight, and he proceeded with the barium enema the following day.

Discussion

Anaphylaxis is a severe allergic reaction of acute onset after exposure to an allergen. It involves a cascading immune reaction that releases inflammatory mediators from mast cells and basophils leading to an acute amplified allergic response, and is potentially fatal if not treated quickly.^{8,9} Anaphylaxis can occur in a biphasic reaction in 20% of patients, during which recurrent symptoms are worse than presenting symptoms after apparent resolution without re-exposure to the trigger. Biphasic anaphylactic reactions are more lethal than monophasic reactions and require hospitalization. A good sense of judgment, history-taking, and proactive treatment is paramount to prevent fatality. Epinephrine is the initial drug of choice in managing this condition, and should be given promptly to those patients initially treated otherwise to prevent rebound symptoms.^{8,10} Failure to use epinephrine in the first 20 minutes of symptom presentation is a risk factor for poor outcomes. Initial symptomatic presentation, oral ingestion of the product, or excessive requirement of epinephrine to control symptoms should warrant prolonged patient observation. Airway maintenance and prevention of hypotension are key to management.¹ Although no clinical trials support use of steroids to prevent biphasic reaction, their use for anaphylaxis is still recommended.¹¹

It is important to note that PEG and its analog can elicit anaphylactic reaction on contact with susceptible patients, even when not orally ingested.¹² Patients who present with PEG-induced allergic reactions should have this product included in their medication allergies. Future gastrointestinal preparation for invasive procedure should be attempted

with alternative products such as Osmoprep[®], Visicol[®] and Prepopik[®]. Both Osmoprep[®] and Visicol[®] are osmotic laxatives that stimulate GI peristalsis. They are effective bowel preparation agents, but can lead to electrolyte imbalance, particularly in patients with kidney disease.¹³ Prepopik[®] is a combination stimulant and osmotic laxative composed of sodium picosulfate, magnesium oxide, and anhydrous citric acid. Just like the osmotic laxatives, this product can lead to severe electrolyte imbalance in susceptible patients.¹⁴

Disclosures

Author contributions: D. Gachoka wrote the manuscript and is the article guarantor.

Financial disclosure: None to report.

Informed consent was obtained for this case report.

Received: December 1, 2014; Accepted: March 11, 2015

References

- Savitz JA, Durning SJ. A rare case of anaphylaxis to bowel prep: A case report and review of the literature. *Mil Med.* 2011;176(8):944–5.
- Assal C, and Watson PY. Angioedema as a hypersensitivity reaction to polyethylene glycol oral electrolyte solution. *Gastrointest Endosc.* 2006;64(2):294–5.
- Stollman N, Manten DH. Angioedema from oral polyethylene glycol electrolyte lavage solution. *Gastrointest Endosc.* 1996;44(2):209–10.
- Co-Minh HB, Demoly P, Guillot B, and Raison-Peyron N. Anaphylactic shock after oral intake and contact urticaria due to polyethylene glycols. *Allergy.* 2007;62(1):92–3.
- Lee SH, Cha JM, Lee JI, et al. Anaphylactic shock caused by ingestion of polyethylene glycol. *Intest Res.* 2015;13(1):90–4.
- Schuman E, Balsam PE. Probable anaphylactic reaction to polyethylene glycol electrolyte lavage solution. *Gastrointest Endosc.* 1991;37(3):411.
- Brullet E, Moron A, Calvet X, et al. Urticarial reaction to oral polyethylene glycol electrolyte lavage solution. *Gastrointest Endosc.* 1992;38(3):400–1.
- Kemp SF, Lockey RF, Simons FE; World Allergy Organization ad hoc committee on epinephrine in anaphylaxis. Epinephrine: The drug of choice for anaphylaxis. A statement of the World Allergy Organization. *World Allergy Organ J.* 2008;1(suppl 7):S18–26.
- Simons FE. Anaphylaxis. *J Allergy Clin Immunol.* 2008;121(suppl 2):S402–7;quiz S20.
- Simons FE, Simons KJ. Epinephrine (adrenaline) in anaphylaxis. *Chem Immunol Allergy.* 2010;95:211–22.
- Lewis J. BET 2: In children, do steroids prevent biphasic anaphylactic reactions? *Emerg Med J.* 2014;31(6):510–2.
- Yamasuji Y, Higashi Y, Sakanoue M. A case of anaphylaxis caused by polyethylene glycol analogues. *Contact Dermatitis.* 2013;69(3):183–5.
- Wruble L, Demicco M, Medoff J, et al. Residue-free sodium phosphate tablets (OsmoPrep) versus Visicol for colon cleansing: A randomized, investigator-blinded trial. *Gastrointest Endosc.* 2007;65(4):660–70.
- Johnson DA, Barkun AN, Cohen LB, et al. Optimizing adequacy of bowel cleansing for colonoscopy: Recommendations from the US multi-society task force on colorectal cancer. *Gastroenterology.* 2014;147(4):903–24.