

# Endoscopic Submucosal Dissection for the Complete Resection of the Rectal Remnant Mucosa in a Patient With Familial Adenomatous Polyposis

Naoki Ishii, MD<sup>1</sup>, Hitoshi Akiyama, MT<sup>1</sup>, Koyu Suzuki, MD<sup>2</sup>, and Yoshiyuki Fujita, MD<sup>1</sup>

<sup>1</sup>Center of Gastroenterology, St. Luke's International Hospital, Tokyo, Japan

<sup>2</sup>Department of Pathology, St. Luke's International Hospital, Tokyo, Japan

## Abstract

A 47-year-old woman underwent prophylactic subtotal colectomy with ileorectal anastomosis (IRA) for familial adenomatous polyposis (FAP) 18 years ago. She underwent 5 transanal endoscopic microsurgies for rectal remnant polyps, and was referred for the treatment of rectal remnant polyp recurrence. Endoscopic submucosal dissection (ESD) was performed to remove multiple polypoid lesions that circumferentially extended throughout the rectal remnant with lesions spreading onto the anastomotic site. The rectal remnant mucosa was resected in 2 pieces without complication. Specimens showed high-grade adenoma but no malignancy. Follow-up colonoscopy showed no recurrence.

## Introduction

Subtotal colectomy with ileorectal anastomosis (IRA) is occasionally performed for patients with familial adenomatous polyposis (FAP) rather than total proctocolectomy with ileal pouch-anal anastomosis (IPAA), because it produces better functional outcomes and decreases the infertility rate after surgery.<sup>1,2</sup> However, neoplasms that occur in the rectal remnant after IRA require additional treatments, including secondary proctectomy.<sup>3</sup> Endoscopic submucosal dissection (ESD) has recently been performed to treat superficial neoplasms of the digestive tract.<sup>4-8</sup>

## Case Report

A 47-year-old woman underwent prophylactic subtotal colectomy with IRA for FAP 18 years ago. She then underwent 5 separate transanal endoscopic microsurgies (TEMs) for the removal of subsequent rectal remnant polyps. Proctoscopy revealed multiple polypoid lesions in the rectal remnant (Figure 1). Biopsy specimens from the polypoid lesions showed high-grade adenoma. Because the polyps circumferentially extended throughout the rectal remnant with the oral portion of the lesions spreading onto the anastomotic site, circumferential ESD was planned for the complete resection of the rectal remnant mucosa.

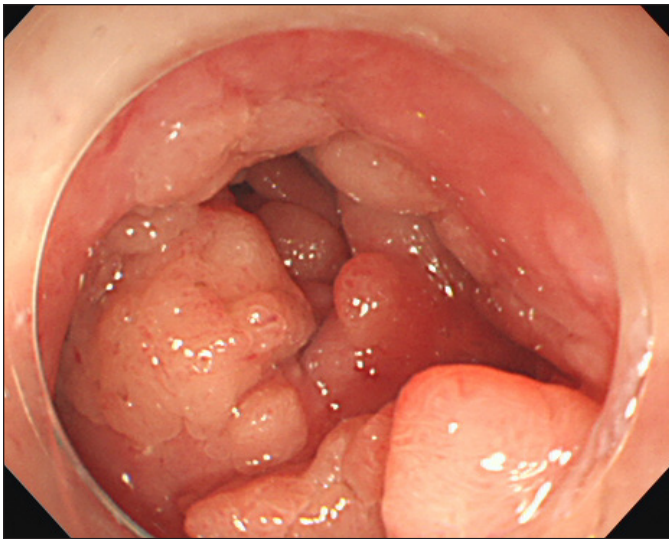
Although the submucosal dissection at the anastomotic site was difficult because of severe fibrosis, the rectal remnant mucosa was completely resected in 2 pieces without perforation using a KD-620LR hook knife (Olympus Medical Systems, Center Valley, PA; Figure 2).<sup>6</sup> Pathology examination of the resected specimens demonstrated high-grade, non-cancerous adenoma. Post-ESD stricture was prevented using a betamethasone suppository and finger bougie. Follow-up proctoscopy performed 12 months after the circumferential ESD showed no recurrence in the rectal remnant (Figure 3). Rectal mucosa was completely replaced by ileal mucosa and the bowel function of the patient was not exacerbated.

*ACG Case Rep J* 2016;3(3):172-174. doi:10.14309/crj.2016.40. Published online: April 15, 2016.

**Correspondence:** Naoki Ishii, Department of Gastroenterology, St. Luke's International Hospital, 9-1 Akashi-cho, Chuo-ku, Tokyo, Japan, 104-8560 (naoishi0328@gmail.com).



**Copyright:** © 2016 Ishii et al. This work is licensed under a Creative Commons Attribution-NonCommercial-NoDerivatives 4.0 International License. To view a copy of this license, visit <http://creativecommons.org/licenses/by-nc-nd/4.0>.

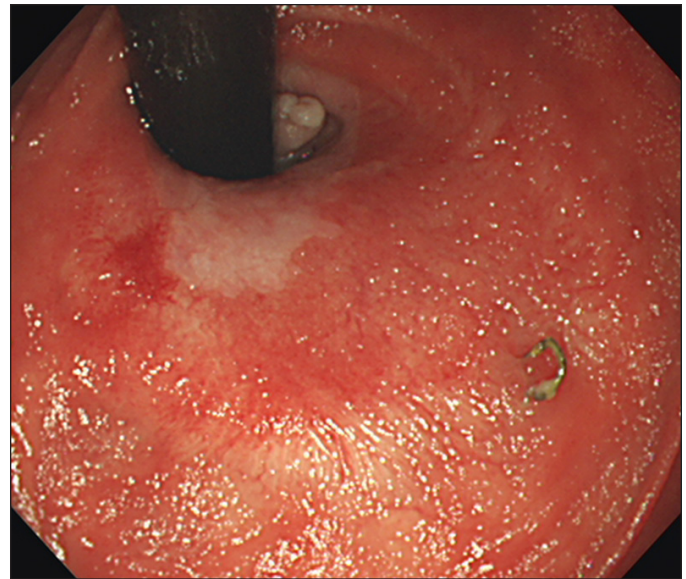


**Figure 1.** Endoscopic view of polypoid lesions extending throughout the rectal remnant.

## Discussion

FAP is an autosomal dominant disease characterized by more than hundreds of adenomatous polyps. FAP increases the risk of colon cancer, and prophylactic colectomy is required to prevent the further development of colon cancer. Colectomy can be either subtotal colectomy with IRA or total proctocolectomy with IPAA. Total proctocolectomy with IPAA is more difficult to perform, and can result in impaired bowel function and an increased risk of infertility. Thus, subtotal colectomy with IRA is preferred, especially in younger patients.<sup>1,2</sup> However, neoplasms can occur in the rectal remnant after IRA, requiring additional endoscopic treatments and/or secondary proctectomy.<sup>3</sup>

In cases such as ours, where many polyps spread onto the anastomotic site and throughout the rectal remnant, treatment by endoscopic mucosal resection (EMR) using snare is difficult. Because ESD has been performed for the resection of large gastrointestinal neoplasms with negligible risk of metastasis,<sup>3-8</sup> we decided to perform circumferential ESD for the resection of the rectal remnant mucosa. Although severe fibrosis was observed within the submucosal layer at the anasto-



**Figure 3.** Follow-up proctoscopy 12 months after ESD showed rectal mucosa was completely replaced by ileal mucosa and no recurrence in the rectal remnant.

mot and post-TEM sites, use of a hook knife enabled precise submucosal dissection of the fibrotic tissues and completion of circumferential ESD without perforation. Stricture following circumferential ESD can be managed with steroid suppositories and finger bougies. We suggest that circumferential ESD is a safe and effective treatment for complete resection of the rectal remnant mucosa after IRA in patients with FAP.

## Disclosures

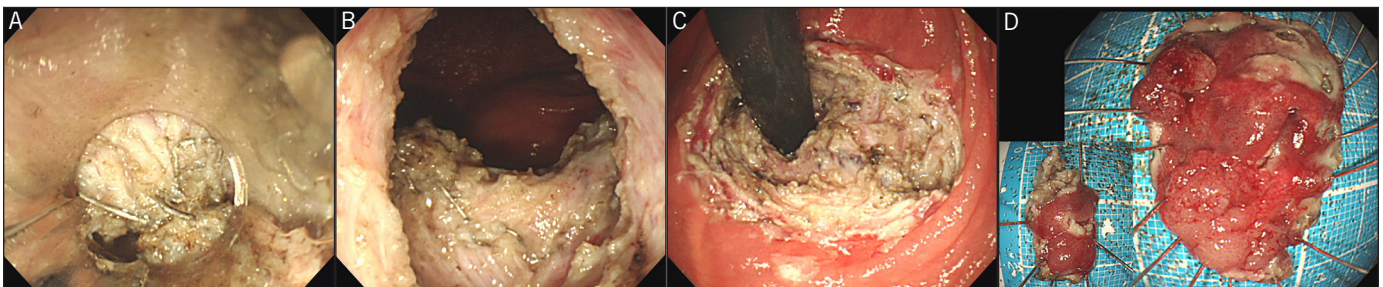
**Author contributions:** The authors contributed equally to the creation of this manuscript. N. Ishii is the article guarantor.

**Financial disclosure:** None to report.

**Informed consent** was obtained for this case report.

This case report was presented as a poster at the ACG Annual Scientific Meeting; October 16-25, 2015; Honolulu, Hawaii.

Received October 20, 2015; Accepted January 15, 2015



**Figure 2.** Endoscopic view of (A) severe fibrosis and surgical staples at the anastomotic site, (B) the post-ESD ulcer in the rectal remnant, and (C) the post-ESD ulcer in retroflexion. (D) The resected specimens measured 36 × 27 mm and 10 × 10 mm.

## References

1. Jagelman DG. Choice of operation in familial adenomatous polyposis. *World J Surg.* 1991;15(1):47–49.
2. van Duijvendijk P, Slors JF, Taat CW, et al. Functional outcome after colectomy and ileorectal anastomosis compared with proctocolectomy and ileal pouch-anal anastomosis in familial adenomatous polyposis. *Ann Surg.* 1999;230(5):648–654.
3. Koskenvuo L, Renkonen-Sinisalo L, Järvinen HJ, et al. Risk of cancer and secondary proctectomy after colectomy and ileorectal anastomosis in familial adenomatous polyposis. *Int J Colorectal Dis.* 2014;29(2):225–230.
4. Ono H, Kondo H, Gotoda T, et al. Endoscopic mucosal resection for treatment of early gastric cancer. *Gut.* 2001;48(2):225–229.
5. Yamamoto H, Kawata H, Sunada K, et al. Successful en-bloc resection of large superficial tumors in the stomach and colon using sodium hyaluronate and small-caliber-tip transparent hood. *Endoscopy.* 2003;35(8):690–694.
6. Oyama T, Tomori A, Hotta K, et al. Endoscopic submucosal dissection of early esophageal cancer. *Clin Gastroenterol Hepatol.* 2005;3(7 Suppl 1):S67–70.
7. Tanaka S, Asayama N, Shigita K, et al. Towards safer and appropriate application of endoscopic submucosal dissection for T1 colorectal carcinoma as total excisional biopsy: Future perspectives. *Dig Endosc.* 2015;27(2):216–222.
8. Ishii N, Akiyama H, Suzuki K, et al. Safety and efficacy of endoscopic submucosal dissection for non-ampullary duodenal neoplasms: A case series. *ACG Case Rep J.* 2015;2(3):146–149.

### Publish your work in ACG Case Reports Journal

ACG Case Reports Journal is a peer-reviewed, open-access publication that provides GI fellows, private practice clinicians, and other members of the health care team an opportunity to share interesting case reports with their peers and with leaders in the field. Visit <http://acgcasereports.gi.org> for submission guidelines. Submit your manuscript online at <http://mc.manuscriptcentral.com/acgcr>.