

# Complete Esophageal Obstruction after Endoscopic Variceal Band Ligation in a Patient with a Sliding Hiatal Hernia

Munthir Mansour, MD<sup>1</sup>, Yousef Abdel-Aziz, MD<sup>1</sup>, Hesham Awadh, MD<sup>1</sup>, Nihar Shah, MD<sup>2</sup>, and Akash Ajmera, MD<sup>2</sup>

<sup>1</sup>Department of Internal Medicine, Joan C. Edwards School of Medicine, Marshall University, Huntington, WV

<sup>2</sup>Department of Gastroenterology, Joan C. Edwards School of Medicine, Marshall University, Huntington, WV

## ABSTRACT

Complete esophageal obstruction is a rare complication of endoscopic variceal banding, with only 6 cases in the English literature since the introduction of endoscopic variceal banding in 1986. We report a case of complete esophageal obstruction following esophageal banding due to entrapment of part of a sliding hiatal hernia. To our knowledge, our case is one of few with esophageal obstruction post-banding, and the first associated with a hiatal hernia. We recommend caution when performing esophageal banding on patients with a hiatal hernia.

## INTRODUCTION

Endoscopic variceal ligation (EVL) is the definitive treatment of choice for active variceal hemorrhage. It is a relatively simple procedure and is associated with fewer complications than endoscopic sclerotherapy. Only 6 cases of complete esophageal obstruction following EVL have been reported in the English literature.

## CASE REPORT

A 65-year-old woman with a history of cirrhosis secondary to alcohol abuse, grade 1 esophageal varices, and a sliding hiatal hernia (SHH) presented with hematemesis. She was found to have esophageal varices 2 years ago and was started on nadolol. On examination, she had scleral icterus, and her laboratory tests were hemoglobin 10.7 g/dL, alanine aminotransferase 71 U/L, aspartate aminotransferase 120 U/L, international normalized ratio 1.4, serum Na 145 mEq/L, serum creatinine 1 mg/dL, and total bilirubin 4 mg/dL. Esophagogastroduodenoscopy (EGD) revealed 4 columns of grade 2 varices in the distal third of the esophagus. Two of the columns showed red wale stigmata. Four ligation bands were successfully deployed.

The patient returned 3 weeks later for a repeat EVL. EGD revealed a small grade 1 varix in the distal third of the esophagus (Figure 1). The patient had a large SHH and had hiccups during banding. Gastric tissue slid upwards unpredictably during her hiccups, and a small amount of gastric tissue was caught in the band when it was deployed. The patient tolerated the procedure well without other complications, and was discharged home. She presented 3 days later for persistent nausea and non-bloodily emesis. She did not tolerate any solids or liquids following the procedure. A barium swallow showed complete obstruction of the distal esophagus.

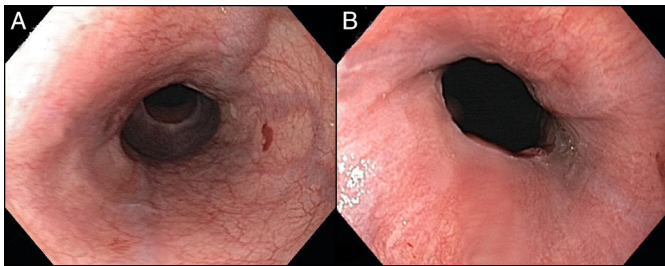
EGD revealed a complete obliteration of the lumen at the gastroesophageal junction. An esophageal band with inadvertent gastric tissue was seen. The tissue was edematous and blocking the lumen (Figure 2). No endoscopic

ACG Case Rep J 2017;4: e8. doi:10.14309/crj.2017.8. Published online: January 18, 2017.

**Correspondence:** Akash Ajmera, Department of Gastroenterology, Joan C. Edwards School of Medicine, Marshall University, 1249 15th St, Erma Ora Byrd Clinical Center, Huntington, WV 25701 (dr.ajmera@gmail.com).



Copyright: © 2017 Mansour et al. This work is licensed under a Creative Commons Attribution-NonCommercial-NoDerivatives 4.0 International License. To view a copy of this license, visit <http://creativecommons.org/licenses/by-nc-nd/4.0>.



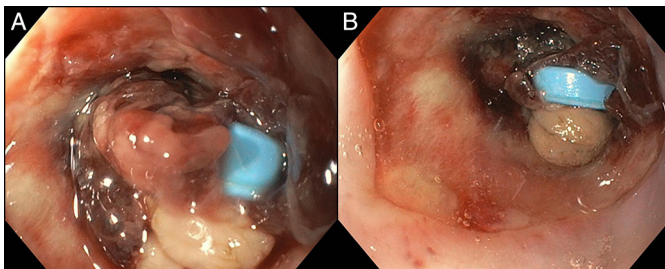
**Figure 1.** Endoscopy showing small esophageal varices with red wale stigmata.

intervention was attempted, and the patient was observed in the hospital. She tolerated a diet after 3 days, and the obstruction resolved spontaneously. She did well until 4 weeks later when she presented with dysphagia. An EGD revealed a stricture at the distal end of the esophagus, with difficulty passing the endoscope (Figure 3). With pressure, the stricture was passed. Over the next 4 months, she required 3 sessions of balloon dilation of the stricture with resolution of her symptoms (Figure 4).

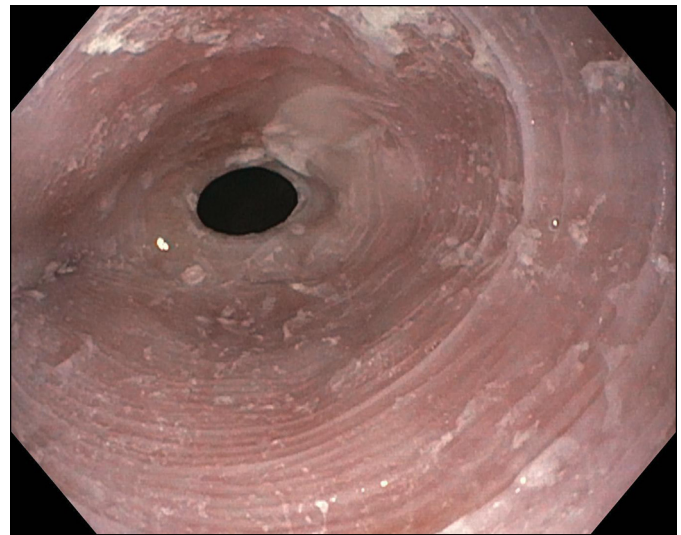
## DISCUSSION

Endoscopic variceal banding works by capturing the varices causing venous occlusion from thrombosis and leading to tissue necrosis. The bands slough off in a few days, leaving a superficial ulceration that rapidly heals. EVL has been associated with fewer complications and mortality than endoscopic sclerotherapy.<sup>1-6</sup> Complications described after EVL include transient dysphagia, stricture formation, ulcers, pneumonia, and spontaneous bacterial peritonitis.<sup>1-6</sup>

Complete esophageal obstruction following EVL is extremely rare. Only 6 prior cases exist in the English literature.<sup>7-12</sup> Esophageal obstruction post-banding may occur secondary to edema and necrosis at the banding area. It is believed that placing a band close to mucosa that is damaged with edema or necrosis may increase the risk of post-ligation obstruction. We believe that allowing appropriate time for the damaged mucosa to heal between banding is crucial to avoid this complication. There is limited evidence to support an optimal time interval. It is likely that smaller varices are more prone to ulceration



**Figure 2.** Esophageal obstruction from banding of inadvertently caught gastric tissue with necrotic tissue and edema surrounding the band.



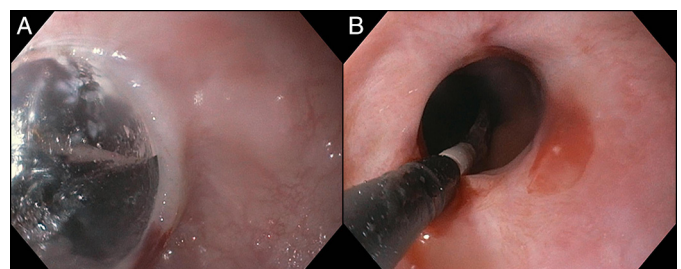
**Figure 3.** Esophageal stricture following esophageal obstruction.

and stricture formation due to greater injury to the surrounding mucosa, thus increasing the risk of post-ligation obstruction.<sup>10</sup> Therefore, particular caution needs to be exercised in selecting the right-sized varix for ligation, avoiding excessive suctioning of mucosa surrounding varices, and a gentle examination of the esophagus following the completion of EVL. One report recommended that EVLs should be applied in a spiral fashion to avoid extensive luminal compromise on one plane.<sup>9</sup>

Our patient had a history of SHH and was hiccupping during the procedure. We believe that hiccupping caused the hiatal hernia to slide up during deployment of the band, causing it to get caught in the band. Gastroenterologists should use caution when banding patients with a hiatal hernia, especially if they are banding in the distal esophagus or near the gastroesophageal junction. Active manipulation to alleviate the obstruction is generally not successful, and conservative management is the accepted approach for esophageal obstruction following EVL.<sup>9-11</sup>

## DISCLOSURES

Author contributions: M. Mansour, Y. Abdel-Aziz, and H. Awadh wrote the manuscript. N. Shah and A. Ajmera edited the manuscript. A. Ajmera is the article guarantor.



**Figure 4.** Balloon dilation of the esophageal stricture.

Financial disclosure: None to report.

Informed consent was obtained for this case report.

Received May 7, 2016; Accepted October 7, 2016

## REFERENCES

1. Saltzman JR, Arora S. Complications of esophageal variceal band ligation. *Gastrointest Endosc*. 1993;39(2):185-6.
2. Stiegmann GV, Goff JS, Michaletz-Onody PA, et al. Endoscopic sclerotherapy as compared with endoscopic ligation for bleeding esophageal varices. *N Engl J Med*. 1992;326:1527-32.
3. Lo GH, Lai KH, Cheng JS, et al. A prospective, randomized trial of sclerotherapy versus ligation in the management of bleeding esophageal varices. *Hepatology*. 1995;22:466.
4. Goff JS, Reveille RM, Stiegmann GV. Three years experience with endoscopic variceal ligation treatment of bleeding varices. *Endoscopy*. 1992;24:401.
5. Schmitz RJ, Sharma P, Badr AS, et al. Incidence and management of esophageal stricture formation from sclerotherapy versus band ligation. *Am J Gastroenterol*. 2001;96:437.
6. Laine L, Cook D. Endoscopic ligation compared with sclerotherapy for treatment of esophageal variceal bleeding: A meta-analysis. *Ann Intern Med*. 1995;123:280.
7. Verma D, Pham C, Madan A. Complete esophageal obstruction: An unusual complication of esophageal variceal ligation. *Endoscopy*. 2009;41:E200-1.
8. Nikoloff MA, Riley TR, Schreiberman IR. Complete esophageal obstruction following endoscopic variceal ligation. *Gastroenterol Hepatol (N Y)*. 2011;7:557-9.
9. Chahal H, Ahmed A, Sexton C, Bhatia A. Complete esophageal obstruction following endoscopic variceal band ligation. *J Community Hosp Intern Med Perspect*. 2013;3(1):10.3402.
10. Nawaz A, Sarwar S, Batul A. Complete esophageal occlusion following esophageal variceal band ligation: An unusual complication: A case report. *Visible Human Journal of Endoscopy*. 2010;9:1-4.
11. de Melo SW. Complete esophageal occlusion after band ligation. *Endoscopy*. 2011;43:E259.
12. Elizondo-Rivera RL. Complete esophageal obstruction after endoscopic variceal band ligation. *Endoscopy*. 2014;46(Suppl 1):E457-8.